

INTRODUCTION:

Instability at the ulnocarpal joint can result from a number of etiologies, but the common thread among these causes for ulnocarpal instability (UCI) is often the presence of pathology in the triangular fibrocartilage complex (TFCC). To our knowledge, the clinical experience reported with UCI has not yet been substantiated by biomechanical evidence that peripheral TFCC tears result in UCI. The aim of the current study is to determine whether disruption of the peripheral TFCC causes ulnocarpal instability. Based on our clinical experience, we hypothesize that an arthroscopically-created tear of the articular disk of the TFCC will cause a significant decrease in ulnocarpal stability on mechanical testing.

METHODS:

24 fresh-frozen human upper extremities with intact elbow to the hand were held with the elbow in 90° flexion, the forearm in pronation and wrist in neutral on a servo-hydraulic loading machine, (Figure #1). A screw in the distal ulna was fixed to the loading actuator and a vertical load was sinusoidally cycled at ¼ Hz while the vertical movement was measured. From the load-displacement curve a range of dorsal-volar motion with minimal resistance (DVRM) was identified and the slope of the curve at the ends of the DVRM were measured and termed the ulnocarpal stiffness.

A standardized 3 mm lesion of the ulnar-sided peripheral TFCC was then created via a single incision with a #15 scalpel blade under direct arthroscopic visualization. (Figure #2). The loading regimen was repeated after the TFCC lesion.




Figure 1: Vertical mechanical loads were placed on the distal ulna while the carpal row was stabilized.

STATISTICAL METHOD:

Mean, standard deviation, skewness and kurtosis were calculated. Because our analysis showed all data to be normally distributed, standard parametric statistical tests were chosen. Two separate paired Student's t-tests were used to compare UC stiffness and DVRM before and after creation of the TFCC tear.

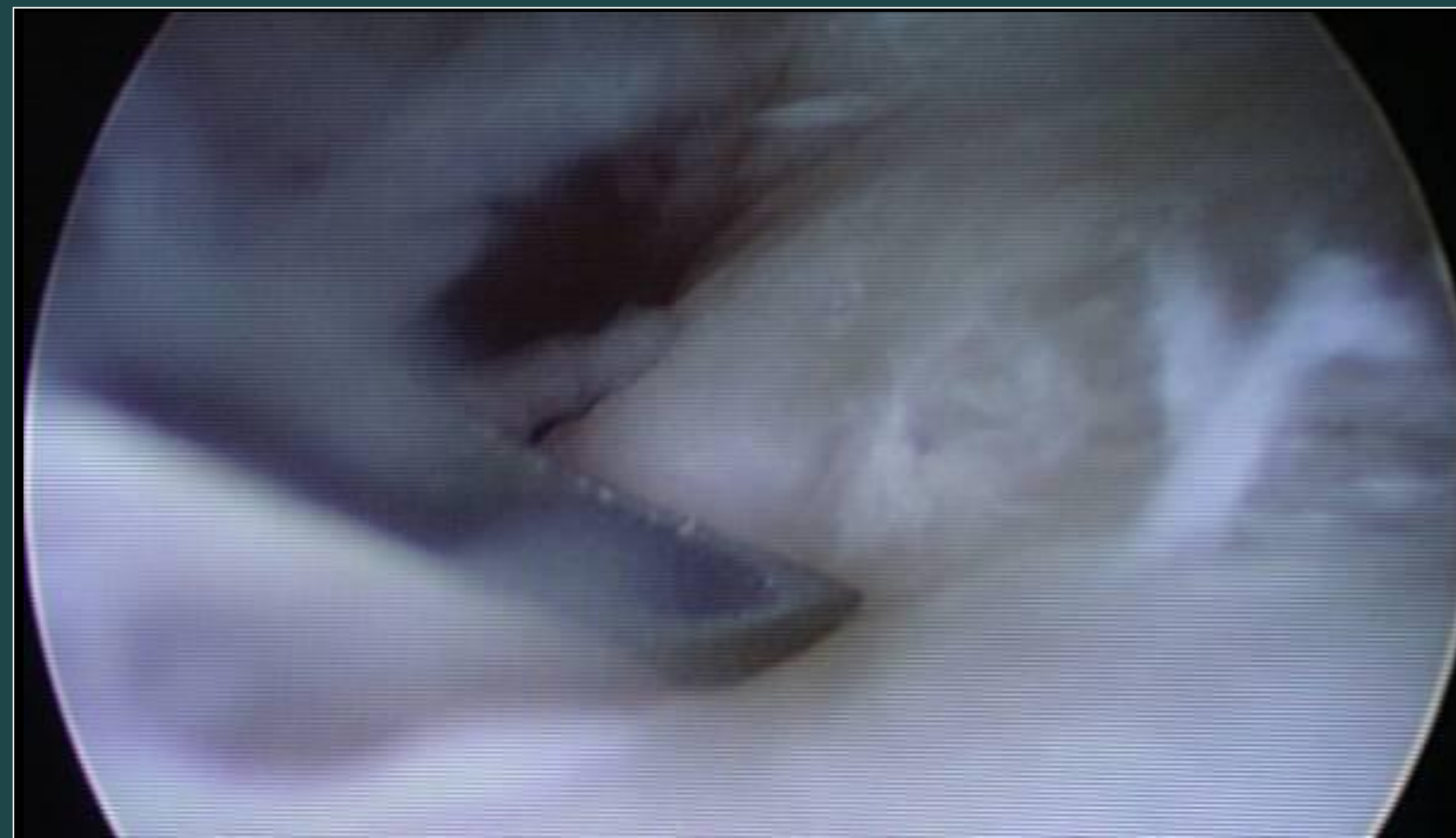

Figure 2: A view through the arthroscope of the lesion being created in the TFCC

RESULTS:

The mean stiffness of the specimens was significantly decreased after creation of a peripheral tear in the articular disk of the TFC ($p=0.003$). The change in DVRM after the articular disk tear was not significantly different ($p=0.08$), see Table 1.

N=20 specimens	Mean	SD	Paired T-Test
Stiffness: baseline	4.86 N/mm	3.68 N/mm	
Stiffness: post tear	3.14 N/mm	2.47 N/mm	$p=0.003^*$
DVRM: baseline	1.82 mm	0.63	
DVRM post tear	2.33 mm	1.38	$p=0.08^{**}$

Table 1: *Lower stiffness indicates more instability
**Higher value of neutral zone indicates more instability

DISCUSSION:

Integrity of the TFCC is essential to maintaining stability of both the distal radioulnar and ulnocarpal joints^{1,2,3,4}. Previous biomechanical^{5,6} and clinical^{7,8} studies have established TFCC pathology as contributory to DRUJ instability, but less attention has been directed to the potential for secondary instability at the UCJ. Although both Palmer⁵ and Melone¹ mention the presence of UCI in their clinical experience of treating patients with TFCC pathology, no previous biomechanical study has attempted to substantiate their clinical findings. In the current study, we have established that a peripheral tear of the articular disk of the TFC significantly increases instability at the ulnocarpal joint.

The current study carries limitations inherent to ex-vivo biomechanical studies. Storage of the specimens may have altered the mechanical properties of the bony and soft tissue structures and their ability to act as dynamic stabilizers of the UCJ.

DISCUSSION cont.:

While the TFCC is composed of many contiguous structures, we chose only to transect the peripheral attachment of the articular disk of the TFCC, representative of a Palmer 1B lesion. Further transection of the ulnocarpal ligaments and the other remaining components of the TFCC in the current experimental model would likely propagate the destabilization of both the UCJ and DRUJ, following the spectrum of instability proposed by Melone and Nathan¹. The current study is the first to establish biomechanical instability at the ulnocarpal joint after a TFCC lesion, particularly at the peripheral attachment of the articular disk. While these findings may seem intuitive in view of prior anatomic⁴ and clinical speculations,^{1,7} these results will help to define the pathomechanics underlying UCI. The presence of UCI after an isolated lesion of the articular disk suggests that both the distal radioulnar and ulnocarpal joints should be evaluated and accounted for in treatment strategies for patients with pathology of the TFCC, even if the ulnocarpal ligaments, ulnar collateral ligament, and ECU subsheath appear unaffected on advanced imaging modalities. Seeing that many surgeons are currently performing DRUJ reconstruction⁸ to treat patients with irreparable TFCC tears, one should evaluate the stability of the UCJ after reconstruction is complete and consider utilizing an adjunctive procedure to stabilize the UCJ if necessary.

SIGNIFICANCE:

A TFCC lesion at the peripheral attachment of the articular disk can cause ulnocarpal instability. Both ulnocarpal and radioulnar stability should be evaluated when assessing TFCC repair techniques and reconstructive procedures, even in the absence of pathology in the other soft tissue components of the TFCC.

REFERENCES:

1. Melone, et.al, CORR,1992;275:65-73
2. Linscheid, et.al, CORR 1992;275:46-55
3. Kauer, CORR.1992;275:37-45
4. Nakamura et.al, JHS,1996;21B:581-6
5. Ruch, et.al, J Arthroscopy Rel Surg, 2003;19:391-6
6. Nishiwaki, et.al, JHS, 2005;30A:719-726
7. Palmer, JHS, 1989;14A:594-606
8. Adams, et.al, J Am Acad Orthop Surg 2007;15:571-575

ACKNOWLEDGEMENTS:

This project was supported in part by The Hand Place, Miami, FL and the Max Biedermann Institute for Biomechanics, Mount Sinai Medical Center, Miami, FL

